

## RESEARCH PAPER

## Evaluation of Hysteroscopic Findings and Histopathologic Report of Endometrium in Postmenopausal Bleeding

Monowara Begum<sup>1\*</sup>, Sabera Khatun<sup>1</sup>, Shirin Akter Begum<sup>1</sup>, Mehriban Amatullah<sup>1</sup>,  
Tasfia Mahmud<sup>2</sup>, Rifat Ara<sup>3</sup>, Mahmud-Un-Nabi<sup>4</sup>, Farhana Khatoun<sup>1</sup>,  
Touhida Nazneen<sup>5</sup>, Jannatul Ferdous<sup>1</sup>

<sup>1</sup>Department of Gynaecological Oncology, Bangabandhu Sheikh Mujib Medical University (BSMMU), Shahbag, Dhaka, Bangladesh, <sup>2</sup>Sirajul Islam Medical College, <sup>3</sup>Department of Gynaecological Oncology, National Institute of Cancer Research and Hospital, Dhaka, Bangladesh, <sup>4</sup>Department of Anesthesiology, Bangabandhu Sheikh Mujib Medical University (BSMMU), Shahbag, Dhaka, Bangladesh, <sup>5</sup>Department of Gynecological Oncology. Munshiganj 250 beds district Hospital, Munshiganj, Bangladesh

### Abstract

**Background:** Women with postmenopausal bleeding have 10%-15% chance of having endometrial carcinoma and therefore the diagnostic work is aimed at excluding uterine malignancy. For accurate diagnosis of cause of postmenopausal bleeding, endometrial abnormalities can be assessed by hysteroscopy and hysteroscopy directed biopsy or fractional curettage.

**Objective:** To compare the hysteroscopic findings with histopathologic report of endometrium in postmenopausal bleeding.

**Methods:** Cross sectional study was conducted in the department of gynaecological oncology in Bangabandhu Sheikh Mujib Medical University over 1 year from June 2019 to May 2020. Thirty women with the complaints of postmenopausal bleeding were enrolled. Each women underwent hysteroscopic evaluation and endometrial tissue was obtained by hysteroscopy directed biopsy as well as fractional curettage in some cases, then sent for histopathology. Results were analyzed to find out sensitivity, specificity, accuracy, positive predictive value and negative predictive value of hysteroscopy, taking histopathological diagnosis as gold standard. Analysis was carried out by using SPSS version 26.

**Results:** Hysteroscopic examination findings and histopathology of endometrium in 30 postmenopausal women, 11(36.6%) cases were found normal both on hysteroscopy and histopathology, among them 4(13.3%) cases were proliferative endometrium, 1(3.3%) was secretory endometrium and 5(16.6%) cases were found atrophic endometrium and 1(3.3%) tissue was insufficient. Hysteroscopic view of normal endometrium showed a sensitivity 100%, specificity 100%, positive predictive value 100%, negative predictive value 100% and accuracy 100%. For Endometrial polyp showed sensitivity, specificity, positive predictive value, negative predictive value and accuracy 100% respectively. For Hyperplasia, hysteroscopy showed sensitivity 100%, specificity 96.2%, positive predictive value 80%, negative predictive value 100% and accuracy 96.7%. Endometrial carcinoma was found in 3(10%) cases and showed sensitivity of 100%, specificity of 96.3%, positive predictive value 75.0%, negative predictive value 100% and accuracy 96.7%. For the atrophic endometrium, sensitivity (100%), specificity (96.0%), positive predictive value (83.3%), negative predictive value (100%) and accuracy (96.7%). 1(3.3%) had in situ endometrial carcinoma and 2(6.6%) had adenomyosis on histopathology.

**Conclusion:** The study concludes that hysteroscopy and directed biopsy or fractional curettage is a highly accurate, sensitive, specific, positive predictive value and negative predictive value for diagnosis of cause of postmenopausal bleeding.

**Keyword:** Hysteroscopy, histopathology, postmenopausal bleeding.

**\*Correspondence:** Monowara Begum, Department of Gynaecological Oncology, Bangabandhu Sheikh Mujib Medical University (BSMMU), Shahbag, Dhaka, Bangladesh.  
E-mail: mbegumnabi2008@gmail.com  
ORCID: 0000-0003-0801-3992

### Introduction

Postmenopausal bleeding can be defined as bleeding per vagina that occurs from the genital tract in any amount, duration and frequency occurring at least one year after menopause.<sup>1</sup> A woman is considered

menopausal, after cessation of menstruation for 1 year. The average age of menopause in Asian women is 46 years, range 45 to 58 years.<sup>2</sup> Any uterine bleeding irrespective of amount and duration during menopause should be considered alarming symptom and needs meticulous evaluation. It may be the sole manifestation of the underlying endometrial cancer at a stage when it can be cured completely with appropriate treatment. In 90% of carcinoma of the endometrium PMB occurs, but only 10%-15% of women with PMB will have endometrial cancer.<sup>3</sup>

Causes of postmenopausal bleeding included- 1) Atrophic endometritis, (30%), 2) Atrophic vaginitis 3) Exogenous estrogen (30%), 4) Endometrial cancer (15%), 5) Endometrial hyperplasia (5%), 6)

Endometrial polyp (10%), 7) Miscellaneous cause (cervical cancer, uterine sarcoma, urethral caruncle, trauma) (10%).<sup>4</sup>

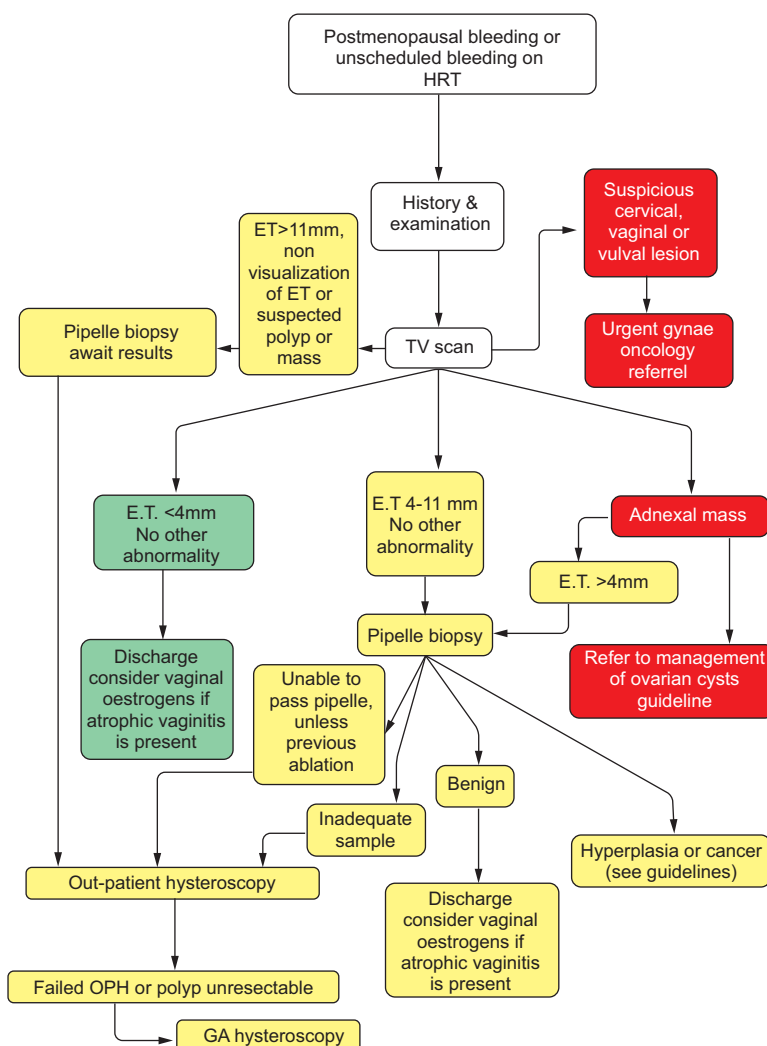
Steps for evaluation of Postmenopausal bleeding is shown in a flow chart

For evaluation of postmenopausal bleeding following steps can be follows:

Step 1: History and examination

For each women with PMB evaluation should be done by careful detailed history, clinical examination including general, abdominal, speculum, per vaginal and rectovaginal examination together with doing some noninvasive and invasive investigations.

### Guideline for post-menopausal bleeding assessment<sup>5</sup>



**Step 2: Sonography:**

Following history and clinical examination, then we do Trans Vaginal Sonogram (TVS) to see endometrial thickness, to segregate of the patients for further procedure.

**Step 3: Endometrial biopsy:**

After the segregation of the patients, endometrial biopsy will be taken by following methods:

a. Fractional curettage

b. Endometrial sampling

c. Hysteroscopy: For evaluation of endometrium in postmenopausal bleeding hysteroscopic direct view and guided biopsy is considered as the gold standard diagnostic procedure.<sup>1,2,3</sup> Hysteroscopy is a procedure that allows to look inside the uterus in order to diagnosis and treatment of postmenopausal bleeding.

Hysteroscopy is done by using a thin, lighted tube with 2.9mm or 4mm 30 degree rigid telescope.<sup>1,6</sup> As a diagnostic procedure it is safe, less time consuming and a low incidence of complication.<sup>6</sup> It is also less invasive than fractional curettage.

By the use of hysteroscope we can get the panoramic view of whole endometrial cavity. Hysteroscopic findings are classified as normal if endometrium is proliferative, secretory, atrophic and hypotrophic and as abnormal when endometrial polyp, submucous fibroid, endometritis, endometrial hyperplasia or endometrial cancer is present.<sup>3,7</sup> The hysteroscopic criteria for suspecting endometrial hyperplasia are a focal or diffuse increase in endometrial thickness, irregular aspect of the endometrial surface, corrugated endometrial hypertrophy without vascularization, a decrease in intraglandular space, cystic formation protruding in to the uterine cavity, and increase in dilated superficial vessels on panoramic view.<sup>3,7</sup>

Hysteroscopic criteria for endometrial cancer are: atypical vessels, irregular and shiny necrotic tissues, somewhat tissues are softened, friable consistency, irregular vascularization, necrotic area and also bleeding may be present.<sup>3,7</sup>

**Advantage:** Hysteroscopy has following advantages.<sup>6,8</sup>

- Minimally invasive procedure
- It is associated with shortened hospital stay and reduced recovery time

- It allows direct visualization of any intrauterine pathology
- Biopsy can be taken under direct vision

**Complications of hysteroscopy:** The overall complication rate for diagnostic and operative hysteroscopy is 2% with serious complication occurring in less than 1% of case.<sup>6,8</sup>

Following complications related to hysteroscopy are-

- Injury to cervix
- Uterine preparation
- Bleeding
- Infection
- Complication related to anaesthesia

Because of invasiveness, inconvenience and cost of hysteroscopy, some authors suggest ultrasonography and endometrial biopsy by fractional curettage as first line of choice for endometrial evaluation but fractional curettage often miss diagnoses of focal intrauterine lesion.<sup>9</sup>

Lee et al<sup>9</sup> concluded that biopsy by fractional curettage may not be reliable for the evaluation of endometrial pathology. The authors suggest that hysteroscopically guided endometrial biopsy can be considered as the gold standard for evaluation of endometrium in postmenopausal bleeding.

Since hysteroscopy alone is not sufficient to exclude endometrial neoplasia,<sup>3</sup> even when the endometrium appear normal on hysteroscopy, endometrium should be sampled for histopathologic evaluation.<sup>3</sup>

So, the combination of hysteroscopy with hysteroscopy directed biopsy potentially serves a diagnostic and therapeutic purpose.<sup>9,10,11</sup>

Several studies had been done for evaluation of endometrium in postmenopausal bleeding and most of the studies showed high sensitivity, specificity, positive predictive value, negative predictive value of hysteroscopy for diagnosis of endometrial pathology.

A study by Tandulwadkar et al<sup>2</sup> showed the sensitivity for endometrial hyperplasia, endometrial polyp and submucous fibroid was 100% and that of endometrial carcinoma was 87.5% and specificity for endometrial hyperplasia, endometrial polyp, submucous fibroid was 100%, for endometrial carcinoma was 98.1%.

Very few studies had been undertaken in Bangladesh for evaluation of endometrium by hysteroscopy in women with postmenopausal bleeding. Therefore the

purpose of the study is to evaluate the endometrium in postmenopausal bleeding by comparing the hysteroscopic gross findings with histopathological report of hysteroscopy directed biopsy and or with fractional curettage as histopathology report is considered as gold standard.

### Objectives

General objective:

To correlate hysteroscopic findings with histopathological diagnosis in postmenopausal bleeding.

Specific objectives:

- To determine the hysteroscopic findings of endometrium in postmenopausal bleeding.
- To evaluate the histopathological report of endometrial tissues obtained by hysteroscopy directed biopsy and or fractional curettage.
- To correlate the hysteroscopic findings with histopathological diagnosis in determination of accuracy.

*Review of Literature:* Postmenopausal bleeding: As the 90% of the carcinoma of the endometrium occurs with PMB. 10-15% of the women with PMB will have endometrial carcinoma.

Postmenopausal bleeding not only cause of endometrial carcinoma, but also due to some benign lesions like atrophic vaginitis, atrophic endometritis, endometrial hyperplasia, endometrial polyp.

*Endometrial carcinoma:* There are two distinct types of endometrial carcinoma

Type 1(80-85%) which is estrogen dependent, Type 2(15-20%) occurs in older population and frequently found in the setting of an atrophic endometrium. Endometrial carcinoma divided into numerous histopathologic subtypes are:<sup>8</sup>

- Endometrial adenocarcinoma
  - Well differentiated
  - Villous glandular
  - Secretory
  - With squamous differentiation
- Mucinous adenocarcinoma
- Papillary serous carcinoma
- Clear cell carcinoma
- Squamous carcinoma
- Poorly differentiated carcinoma:<sup>8</sup>

*Endometrial hyperplasia:* In broad terms, endometrial hyperplasia relates to excessive cellular proliferation leading to an increased volume endometrial tissue, where an increased endometrial gland and stroma at a ratio of >1:1.

Type of hyperplasia:

- Simple hyperplasia (Cystic glandular hyperplasia)- here glands show hypertrophy rather than hyperplasia.
- Complex hyperplasia (Adenomatous Hyperplasia)- with or without atypia.
- Atypical hyperplasia: Both simple and complex hyperplasia can be associated with cytologic atypia. Risk of hyperplasia progressing to carcinoma is related to the presence and severity of cytologic atypia.<sup>8</sup>

*Endometrial Polyp:* It is found either in single or multiple. Single endometrial polyp is common, specially in the postmenopausal women. Mostly they are symptom less, they often found surprisingly on opening excised organ.

Symptoms are more likely when the tip of the polyp becomes necrotic and ulcerative. TVS reveals a thickened endometrial shadow but certain diagnosis made by hysteroscopy.<sup>8</sup>

*Atrophic endometritis:* Usually non-cancerous condition occurs due to lack of estrogen in postmenopausal women.

More than 30% PMB occurs due to atrophic endometritis.<sup>4</sup>

*Trans Vaginal Sonogram (TVS):* All patients with postmenopausal bleeding will be subjected to a TVS it will be measured as the maximum distance between two myometrial interfaces on longitudinal scan. Endometrial Carcinoma typically present as the thickening of the endometrium. Cut off value of endometrial thickness in postmenopausal women 5mm or less:<sup>3,17</sup>

*Fractional curettage:*

Fractional curettage: It is a diagnostic procedure by which thorough curettage done to obtain specimen from endocervix and endometrium separately.

Fractional curettage began with the introduction of the dilatation of cervix and curettage of endometrium in the 19<sup>th</sup> century and since then it has been considered as a gold standard diagnostic procedure

for postmenopausal bleeding and abnormal uterine bleeding as well as therapeutic for removing endometrial polyp that causes abnormal bleeding and also exclude malignancy.<sup>12</sup>

There is some drawback in fractional curettage, it is blind procedure, more invasive and sometime missing of diagnosis of intrauterine focal lesion and polyp.<sup>1,10</sup> It has low sensitivity and specificity than hysteroscopy.<sup>1</sup>

Complication of fractional curettage: injury to the cervix, uterine perforation, injury to the gut and infection.

**Hysteroscopy:** The development of hysteroscopy is rooted in the work of Pantaleoni, who first reported uterine endoscopy in 1869. He evaluated a 60 years old lady with therapy resistant bleeding and detected a polypoid growth in the uterus on hysteroscopy.

Hysteroscopy is a minimally invasive procedure involving the direct inspection of the cervical canal and endometrial cavity through a rigid, flexible or a contact hysteroscope.<sup>8,13</sup>

Hysteroscopic system comprises of a rigid telescope of different diameters (2-4mm) and a variety of viewing capabilities are available (0°, 12°, 30°, 70°). There is an outer sheath for instillation of the distension media. Various types of distension media are used at the time of hysteroscopy, media can be either gaseous or liquid.

The most popular hysteroscope is a 4mm, 30° telescope with a 5.5mm outer sheath for diagnostic as well as operative hysteroscopy.<sup>6,8</sup>

Hysteroscopy has both diagnostic and therapeutic indications-

- Diagnostic indication:
  - Diagnosis of causes of abnormal bleeding such as menorrhagia, irregular bleeding and AUB in perimenopausal women.
  - Diagnosis of causes of postmenopausal bleeding
  - Diagnostic workup for infertility
- Therapeutic indication:
  - Treatment of AUB by endometrial ablation
  - Polypectomy, removal of submucous fibroid in postmenopausal bleeding
  - Adhesiolysis

El-Mowafi et al<sup>14</sup> conducted a study including forty two patients attended the outpatient clinic in Benha University Hospitals, Egypt with postmenopausal bleeding. The aim of the study to compare prospectively TVS and hysteroscopy findings in women with postmenopausal bleeding, with the histopathological results of the D&C biopsy. Most commonly found on hysteroscopy atrophic endometrium 16 in cases, endometrial hyperplasia found in six cases, endometrial carcinoma was 1, histopathology confirmed atrophic endometrium 19, endometrial hyperplasia 8, endometrial carcinoma 2.

Lasmar et al<sup>6</sup> conducted a study to describe the prevalence of hysteroscopic findings and histologic diagnoses in patients with abnormal uterine bleeding (AUB). Endometrial polyp was the most frequent hysteroscopic finding, accounting for 1,374 (33.9%) cases. Normal uterine cavity and cervical canal were found in 814 (20.1%) patients. Submucous fibroids were diagnosed in 302 (7.5%) women. Normal endometrium was the most frequent histologic diagnosis, accounting for 1,888 (46.6%) cases. Endometrial polyp was found in 1,115 (27.5%) patients. Endometrial hyperplasia was diagnosed in 613 (15.1%) and endometrial cancer in 105 (2.6%) women.

Tandulwadkar et al<sup>2</sup> conducted a study, hysteroscopy in postmenopausal bleeding. They found atrophic endometrium on hysteroscopy 39 and histopathology confirmed 40, endometrial hyperplasia found on hysteroscopy 4 and histopathology confirmed, endometrial carcinoma were found 7 on hysteroscopy and histopathology confirmed 8.

Elfayomy et al<sup>15</sup> A study done on role of hysteroscopy in the detection of endometrial pathology in women presenting with postmenopausal bleeding and thickened endometrium. Most common hysteroscopic findings were polyp followed by endometrial hyperplasia and endometrial carcinoma Though histopathology confirmed all polyp but endometrial hyperplasia and endometrial carcinoma were more than hysteroscopic findings. So the sensitivity for endometrial hyperplasia and endometrial carcinoma were less than other study.

Pop-Trajkovic-Dinic et al<sup>16</sup> conducted a study to define the significance of hysteroscopy as a diagnostic procedure for the evaluation of patients with postmenopausal bleeding. The sensitivity of hysteroscopy in the detection of intrauterine pathology

was 100%, the specificity 81%, the positive predictive value 92% and the negative predictive value 100%.

Loiacono et al<sup>3</sup> conducted a retrospective study; most common findings were endometrial polyp, all were confirmed by histopathology, endometrial hyperplasia found in 55 on hysteroscopy among 7 were endometrial carcinoma on histopathology, Endometrial carcinoma found 22 on hysteroscopy and histopathology confirmed 17. For endometrial hyperplasia, hysteroscopy showed a sensitivity, specificity, PPV and NPV of 81, 96, 87 and 93%, respectively, in the AUB group. The sensitivity of hysteroscopy for endometrial cancer was 63%, the specificity 97%, the PPV 77%, and the NPV 95%.

Sarvi et al<sup>17</sup> conducted a study to investigate the histologic and hysteroscopic findings of postmenopausal women with uterine bleeding. They found mostly endometrial polyp on hysteroscopy and confirmed by histopathology. Endometrial hyperplasia were 11 and confirmed by histopathology and endometrial carcinoma 3 on hysteroscopy, 1 was confirmed by histopathology. The sensitivity, specificity, positive and negative predictive values of hysteroscopy for polyp 100% respectively. For endometrial carcinoma sensitivity, specificity, ppv, npv 100%,97%,33% and 100% respectively.

Sharma et al<sup>13</sup> conducted a study to evaluate the hysteroscopy finding in diagnosis of AUB and its correlation with ultrasonography finding and histopathological reports. Hysteroscopy correctly diagnosed atrophic endometrium, polyp and endometrial carcinoma all were confirmed by histopathology.

Trojano et al<sup>7</sup> performed a retrospective study involving case records of 295 asymptomatic postmenopausal women with a thickened endometrium >5 mm diagnosed by transvaginal sonogram (TVS). Patients (women) underwent hysteroscopy with biopsy. When the hysteroscopic findings were normal, a sensitivity of 100%, specificity of 98.6%, PPV of 95.2%, and NPV of 100% were achieved. For polyps and myomas, were 100%, 98.7%, 99.5%, and 100%, respectively. In case of endometrial hyperplasia, a sensitivity of 66.7%, a specificity of 100%, a PPV of 100%, and a NPV of 98.1% were achieved. For endometrial cancer hysteroscopy, sensitivity, specificity, PPV, and NPV were 100%, 99.6%, 75%, and 100%, respectively.

Junnare et al<sup>18</sup> conducted a study to evaluate the efficacy and accuracy of TVS and hysteroscopy in women with postmenopausal bleeding (PMB). One hundred postmenopausal women with vaginal bleeding

underwent TVS and hysteroscopy. Hysteroscopy was successful in 98 patients. Endometrial histopathology revealed proliferative, secretory and atrophic endometrium in 26, 7 and 23 patients respectively. Polyp was diagnosed in 13 patients. Endometrial hyperplasia was detected in 11 patients and endometrial malignancy in 14 patients. Hysteroscopy had sensitivity of 95.2%, specificity of 92.8%, with diagnostic accuracy of 93.8%.

Solanki et al<sup>1</sup> conducted a study on role of diagnostic hysteroscopy in evaluation of postmenopausal bleeding. To correlate the diagnosis by TVS, hysteroscopy and histopathological diagnosis. They found endometrial hyperplasia 30% on hysteroscopy and histopathology confirmed 33.33%, Atrophic endometrium 20% on both hysteroscopy and histopathology ,polyp showed 6.67% on both hysteroscopy and HPE, Sub mucous myoma on both hysteroscopy and HPE showed 3.33% and endometrial carcinoma found 3.33% on both hysteroscopy and HPE.

Bhoj and Yadav<sup>19</sup> conducted a study to compare the diagnostic accuracy of hysteroscopy and transvaginal ultrasonography in diagnosis of postmenopausal bleeding. Authors found that in 40 patients (50%), the cause of postmenopausal bleeding was atrophic endometrium followed by endometrial hyperplasia seen in 14 patients (17.5%). Hysteroscopy had higher overall sensitivity, specificity, NPV and accuracy as compared to transvaginal ultrasonography. Hysteroscopy was found to be highly accurate in diagnosing endometrial carcinoma (100%) and endometrial polyps (100%). However, both methods showed similar accuracy (97.5%) in diagnosis of proliferative endometrium and hyperplasia.

It is revealed that, most studies with hysteroscopy, TVS and fractional curettage done for evaluation of endometrium in postmenopausal bleeding to know the accurate diagnosis and prompt treatment. Most of studies showed high sensitivity, specificity, PPV, NPV and accuracy of hysteroscopy and directed biopsy then TVS and fractional curettage. Nowadays hysteroscopy and directed biopsy considered as a gold standard for evaluation of postmenopausal bleeding.

## Materials and Methods

*Study design:* Cross sectional observational study.

*Place of Study:* Department of Gynecological Oncology Bangabandhu Sheikh Mujib Medical University, Dhaka

**Duration of study:** One year from approval date of IRB, from June 2019 to May 2020.

**Study population:** Menopausal women with postmenopausal bleeding attending inpatient and outpatient department of Gynecological oncology, BSMMU, Dhaka.

**Sample Size:**

Sample size was calculated by using this formula

$$n = \frac{z^2 pq}{d^2}$$

Here,

n = Sample size

z = 1.96 (at 5% level of significance or 95% confidence level).

p = Prevalence or proportion of occurrence 2% = 0.02

q = 1 - p = 1-0.02 = 0.98

d = Acceptable (allowable) error 5% (0.05).

So,

$$\begin{aligned} \text{So, } n &= \frac{z^2 pq}{d^2} \\ &= \frac{(1.96)^2 \times 0.02 \times 0.98}{(0.05)^2} \\ &= \frac{3.8416 \times 0.0196}{0.0025} = 30.118 \approx 30 \end{aligned}$$

Finally, targeted sample size 30.<sup>20</sup>

**Sampling method:** Purposive sampling was done according to the availability of the women who fulfilled the inclusion and exclusion criteria.

**Selection criteria:**

**Inclusion Criteria:**

- Menopausal women with uterine bleeding
- Age 45-75 years

**Exclusion criteria:**

- Women on hormone replacement therapy
- Postmenopausal bleeding due to vulvar, vaginal, cervical, anal and urethral causes excluded by proper history taking and clinical examination including per vaginal and recto vaginal.
- On anticoagulant therapy
- Surgical menopause
- TVS showing adnexal pathology.
- Women with severe comorbidity

**Operational definitions**

**Postmenopausal bleeding:** Postmenopausal bleeding can be defined as uterine bleeding in any amount, duration even single episode occurring at least one year after menopause. Causes of postmenopausal bleeding are- 1) atrophic endometritis 2) exogenous hormone therapy 3) endometrial carcinoma 4) Endometrial hyperplasia and 5) endometrial polyp.<sup>4</sup>

**Classification of socio economic condition according to:**

Modified Kuppuswamy scale (update for February 2019)<sup>21</sup>

Education of head of family	Score
Professional degree	7
Graduate or postgraduate	6
Intermediate or post high school diploma	5
High school certificate	4
Middle school certificate	3
Primary school certificate	2
Illiterate	1
Occupation of head of family	
Professional (white collar)	10
Semi-professional	6
Clerical, shop-owner/farm	5
Skilled worker	4
Semi-skilled worker	3
Unskilled worker	2
Unemployed	1

Monthly income of family(Rupees)<sup>21</sup>

In 2001 (Base year)	In 2017 (January 2017 CPI)	In 2019 (February 2019 CPI)	Score
>15,197	>41,430	>52,734	12
7,595-15,196	20,715-41,429	26,355-52,733	10
5,694-7,594	15,536-20,714	19,759-26,354	6
3,793-5,693	10,357-15,535	13,161-19,758	4
2,273-3,792	6,214-10,356	7,887-13,160	3
761-2,272	2,092-6,213	2,641-7,886	2
£760	£2,091	£2,640	1

Socioeconomic class	Total score
I Upper	26-29
II Upper middle	16-25
III Lower middle	11-15
IV Upper lower	5-10
V Lower	01-04

**Hysteroscopy:** Hysteroscopy is a minimally invasive procedure, involving the direct inspection of the cervical canal and endometrial cavity through a rigid, flexible, or a contact hysteroscope. Hysteroscopic system comprises of a rigid telescope of different diameters (2-4 mm) and a variety of viewing capabilities are available (0°,12°,30°,70°) and there is an outer sheath for instillation of the distention media.<sup>8</sup>

**Fractional curettage:** It is a diagnostic procedure by which thorough curettage done to obtain specimens from endocervix and from endometrium separately. For evaluation of endometrium in PMB, it is also considered as a gold standard diagnostic procedure but it is more invasive with low sensitivity and specificity.<sup>1,10</sup>

**Hysteroscopic Directed biopsy:** Tissue biopsy taken from suspicious area of endometrium under guidance of hysteroscope.

Variables:

Independent Variables: -

- Hysteroscopic diagnosis of cause of postmenopausal bleeding.

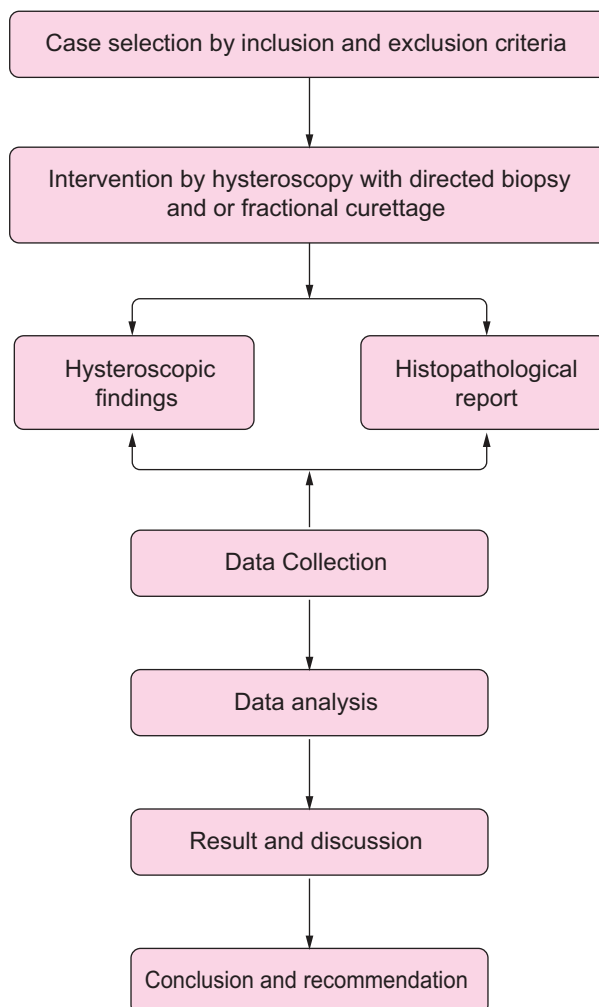
Dependent Variables: -

- Histopathological report

Other Variables:

- Age
- Parity
- Occupation
- Socio-economic status
- Educational status

Flow chart showing sequence of tasks:





**Study Procedure:**

- After ethical clearance from Institutional Review Board (IRB), women having PMB who fulfilled the selection criteria were selected as study population.
- 30 women were taken in this study.
- Women were selected from outpatient department of gynecological oncology.
- Women were informed about the purpose of the study, diagnostic procedure and ethical issue. Details of the study was explained to each women and informed oral and written consent from the responded was obtained.
- Following selection, of women with postmenopausal bleeding were evaluated carefully by proper history including age, obstetrical history and duration since menopause, duration, amount and pattern of postmenopausal bleeding, history of gynecological operation.
- Thorough general and systemic examination was done including pelvic and rectal examination to exclude causes of postmenopausal bleeding like vulvar, vaginal, cervical, anal and urethral lesion.
- Women were informed that hysteroscopy and fractional curettage both are invasive procedure and general anaesthesia will be required.
- Transvaginal sonography will be done in all women with to see the endometrial thickness and exclude adnexal pathology.
- Then diagnostic procedure was done by introducing hysteroscopy by senior oncologists.
- First endocervical tissues were taken then cervix gently dilated prior to introducing the hysteroscope.
- Following introducing of hysteroscopy, directed biopsy was taken from suspicious area of endometrium or if there were any abnormalities found.
- If any polyp or submucous fibroid were found removed at the same time.
- Fractional curettage was done when hysteroscopy showed normal or atrophic endometrium.
- All the specimens immediately placed in 10% formaldehyde separately and sent to the pathology laboratory for histopathological examination.

- For each and every subject separate data collection sheet was used.
- Data were collected from the women on variable of interest using the structured designed by interviewing, observing and thorough clinical examination as well as recorded from hysteroscopic findings and histopathological diagnosis report.

**Data Collections instrument:**

- Data Collection Sheet
- Hysteroscopic findings
- Histopathology report

**Data Processing and Analysis:** At the end of data collection all reports including hysteroscopic findings and histopathological diagnosis was checked and rechecked for omission, inconsistencies and improbabilities. After that, data was cleaned, coded and entered into the computer. For comparing the hysteroscopic findings with histopathological results validity test was used to determine the power of concordance between histopathological diagnosis and hysteroscopic findings. Difference was considered significant for values of  $p < 0.05$ . Sensitivity, specificity, negative predictive values (NPV), positive predictive values (PPV) and accuracy of hysteroscopy was calculated. Data analysis was performed by statistical package for social science (SPSS) version 26.

**Statistical Analysis:** The result of hysteroscopy and histopathological report were recorded on prescribed proforma systematically and statistical analysis was done by using SPSS (Statistical Package for Social Science) Version 26.

**Data Presentation:** Results were presented in the form of tables, figures where applicable.

**Ethical consideration:** Prior to commencement of this study the research protocol was approved by the Institutional Review Board (IRB) of BSMMU, Dhaka. The aim and objectives of the study along with its procedure, risk and benefits of this study was explained to the women in easily understandable local language and then informed consent was taken from each women both orally and written forms. Those who refused to take part in the study were excluded.

The following ethical issues were addressed accordingly:

1. Strict confidentiality and security of data related to patient was maintained. The presentation of data and information related to patient was documented anonymously.
2. There is no additional risk or safety concerned due to research process to either patient or researcher.
3. There is no potential conflict of interest in this study and an entirely an academic research process.

Procedure of maintaining confidentiality:

1. For safeguarding confidentiality and protecting anonymity each of the patients were given a special ID no. which was followed during examination and each and every step of the procedure.
2. A signed informed consent was taken from the women convincing that privacy of the women were maintained.
3. A data collection was enclosed for which a short interview was required.
4. No experimental new drug was administered.

#### Utilization of the study result:

This study is designed to know the actual cause of PMB and accurate diagnosis by hysteroscopy and histopathology in PMB. This study may help the clinician to take the essential steps to evaluate the endometrium for the diagnosis of cause of postmenopausal bleeding.

#### Results

This cross sectional observational study was conducted in the Department of gynecological oncology in BSMMU. A total 30 participants were selected following selection criteria.

Table I shows, Majority women 14 (46.7%) belong to age group 50-55 yrs, mean age of the participants were 54.3±6.12. Majority women 93.3% were multipara, most women passed primary level 12 (40.0%), 27(90.0%) were housewives and most of the women came from middle class family 23 (76.7%).

**Table I:** Socio - demographic characteristics of the participants (n=30)

Age group (years)	Frequency	Percentage
45-49	3	10.0
50-55	14	46.7
>55	13	43.3
Mean±SD (years)	54.3±6.12	
Parity		
Primipara	2	6.7
Multipara	28	93.3
Educational status		
Illiterate	9	30.0
Primary	12	40.0
SSC	5	16.7
HSC	3	10.0
Graduate	1	3.3
Occupation		
Housewife	27	90.0
Service holder	3	10.0
Socioeconomic status		
Lower middle class	6	20.0
Middle class	23	76.7
Upper class	1	3.3

Table II There were found 19(63.3%) patients with abnormal endometrial growth like endometrial polyp, endometrial hyperplasia and endometrial carcinoma.

Table III hysteroscopic directed biopsy revealed most frequent found endometrial polyp 30.0% followed by Endometrial hyperplasia 13.3% and Endometrial carcinoma 10.0%. Fractional curettage showed proliferative endometrium 13.3% and atrophic endometrium 16.7%.

Table IV shows, most hysteroscopic abnormal findings were endometrial polyp 9 (30.0%) all were confirmed by histopathology, followed by endometrial hyperplasia found 5(16.7%), histopathology confirmed 4 (13.3%), endometrial carcinoma found 4(13.3%) and histopathology confirmed 3(10.0%). Normal findings on hysteroscopy 11(36.7%) among them Proliferative

endometrium 4(13.3%) and Atrophic endometrium 5(16.7%) on histopathology.

Table V shows accuracy of hysteroscopy for diagnosis of cause of postmenopausal bleeding, hysteroscopy view of normal findings showed sensitivity of 100%, specificity of 100%, PPV 100%, NPV 100% and accuracy 100%.

For atrophic endometrium hysteroscopy showed sensitivity, specificity, PPV, NPV and accuracy of 100%, 96%, 83.3%, 100% and 96.7% respectively.

The sensitivity, specificity, PPV, NPV and accuracy for hysteroscopic endometrial polyp were 100%, 100%, 100%, 100%, and 100% respectively.

For endometrial hyperplasia, hysteroscopy showed sensitivity, specificity, PPV, NPV and accuracy of 100%, 96.2%, 80.0%, 100% and 96.7 respectively.

The sensitivity, specificity, PPV, NPV and accuracy for endometrial carcinoma were 100%, 96.3%, 75.0%, 100% and 96.7%, respectively.

**Table II:** Distribution according to hysteroscopic findings (n=30)

Hysteroscopic findings	No of cases	Percentage
Normal endometrium	5	16.6%
Atrophic endometrium with bleeding vascular patches	6	20.0%
Endometrial polyp	9	30.0%
Extensive polypoidal endometrium suggest: endometrial hyperplasia	5	16.7%
Endometrial growth with bleeding surface suggest: endometrial carcinoma	4	13.3%
Submucous fibroid	1	3.3%

**Table III:** Histopathological diagnosis of endometrium, tissues obtained by hysteroscopic directed biopsy and fractional curettage (n=30)

Endometrial tissues obtained by procedure	No of cases	Percentage
Hysteroscopic directed biopsy	19	63.3%
Endometrial polyp	9	30.0%
Endometrial hyperplasia	4	13.3%
Endometrial carcinoma	3	10.0%
Adenomyosis	2	6.6%
In situ carcinoma	1	3.3%
Fractional curettage	11	36.7%
Proliferative endometrium	4	13.3%
Secretory endometrium	1	3.3%
Atrophic endometrium	5	16.7%
Insufficient tissue	1	3.3%

**Table IV:** Association between gross hysteroscopic findings and histopathological diagnosis of endometrium (n=30)

Histopathological diagnosis	Hysteroscopic diagnosis						Total
	Normal endometrium	Atrophic endometrium with bleeding vascular patches	Endometrial polyp	Extensive polypoidal endometrium suggests: Endometrial hyperplasia	Irregular endometrial growth with bleeding surface suggest: Endometrial carcinoma	Submucous fibroid	
Proliferative endometrium	4	0	0	0	0	0	4(13.3%)
Secretory endometrium	1	0	0	0	0	0	1(3.3%)
Atrophic endometrium	0	5	0	0	0	0	5(16.7%)
Insufficient tissues	0	1	0	0	0	0	1(3.3%)
Endometrial polyp	0	0	9	0	0	0	9(30.0%)
Endometrial hyperplasia	0	0	0	4	0	0	4(13.3%)
Adenomyosis	0	0	0	1	0	1	2(6.6%)
Endometrial carcinoma	0	0	0	0	3	0	3(10.0%)
In situ endometrial carcinoma	0	0	0	0	1	0	1(3.3%)
Total	5(16.7%)	6(20.0%)	9(30.0%)	5(16.6%)	4(13.3%)	1(3.3%)	30(100.0%)

**Table V:** Accuracy of hysteroscopy for diagnosis of cause of postmenopausal bleeding

Diagnosis	Hysteroscopy				
	Sensitivity	Specificity	PPV	NPV	Accuracy
Normal	100.0	100.0	100.0	100.0	100.0
Atrophic endometrium	100.0	96.0	83.3	100.0	96.7
Endometrial polyp	100.0	100.0	100.0	100.0	100.0
Endometrial hyperplasia	100.0	96.2	80.0	100.0	96.7
Endometrial carcinoma	100.0	96.3	75.0	100.0	96.7

## Discussion

The present study was carried out to evaluate the endometrium of patients having post menopausal bleeding by hysteroscopic findings and histopathological diagnosis. This study was carried out in the department of gynaecological oncology in Bangabandhu Sheikh Mujib Medical University. 30 women with postmenopausal bleeding were enrolled in this study.

In present study majority of the women 14(46.7%) belonged to age group 50-55 years followed by 9(30.0%) to age group 60-65 years. The mean age was 54.3±6.12 years ranging from 45 to 75 years. In accordance with present study Solanki et al<sup>1</sup> reported 83.34% of patients in age group >55 years. Sharma et al<sup>13</sup> reported age range of 45 to 64 years with the postmenopausal bleeding.

In present study among 30 postmenopausal women 93.3% were multiparous. Bhoj and Yadav<sup>19</sup> also

reported 97.5% women to be multiparous which was consistent with present study.

Regarding educational status of women in present study, most of the women passed primary education 12(40.0%).

Among 30 women ,27(90.0%) were house wivess and 3(10.0%) were service holder in present study.

In present study most of women came from middle class 23(76.7%) followed by lower middle class 6(20%) only one came from upper class.

In present study comparing hysteroscopic findings with histopathological results of 30 postmenopausal women, hysteroscopy showed normal findings in 5 cases. Among them, histopathology confirmed 4(13.3%) cases proliferative, 1(3.3%) secretory endometrium.

Hysteroscopy showed 6(20.0%) cases atrophic endometrium which also considered normal findings,

5 (16.7%) cases confirmed by histopathology and 1(3.3%) was insufficient tissue. Solanki et al<sup>1</sup> showed atrophic endometrium 6(20%) among 30 cases that is compatible with present study. Tandulwadkar et al<sup>2</sup> found atrophic endometrium in 66.6% that is not similar with present study.

Hysteroscopic guided biopsy avoided in normal endometrium and atrophic endometrium in present study because there is more chance of getting insufficient tissues for biopsy. For these fractional curettage was done on normal findings of hysteroscopy.

So hysteroscopy directed biopsy only taken from suspicious area and abnormal findings on hysteroscopy.

The abnormal findings on hysteroscopy were:

Endometrial polyp 9(30.3%) which were confirmed by histopathologically. This findings were accordance with the study by Lasmar et al<sup>6</sup> that endometrial polyp were frequent findings. Solanki et al<sup>1</sup> found endometrial polyp 2(6.67%) that is not consistent with present study.

Endometrial hyperplasia diagnosed in 5(16.6%) cases by hysteroscopy and histopathologically confirmed 4(13.3%) of them and 1(3.3%) was adenomyosis. Solanki et al<sup>1</sup> showed endometrial hyperplasia 10(33.3%) that is higher than present study. Tandulwadkar et al<sup>2</sup> found endometrial hyperplasia in 6.66%.

Endometrial carcinoma was diagnosed in 4(13.3%) by hysteroscopy and histopathologically confirmed 3(10.0%) as endometrial carcinoma and 1(3.3%) in situ endometrial carcinoma. Solanki et al<sup>1</sup> found endometrial carcinoma 1(3.3%) among 30 cases that was not agreement with present study. Tandulwadkar et al<sup>2</sup> found endometrial carcinoma in 13.3% and Bhoj M et al<sup>19</sup> found 10% endometrial carcinoma, both study compatible with present study.

Submucous fibroid was observed in one case on hysteroscopy and histopathologically it was adenomyosis.

In present study, accuracy of hysteroscopy:

For normal findings showed a sensitivity of 100%, specificity 100%, PPV 100% and NPV 100% and accuracy 100%.

For atrophic endometrium, hysteroscopy showed a sensitivity 100%, specificity 96.0%, PPV 83.3%, NPV

100% and accuracy 96.7%. In accordance, Trojano et al<sup>7</sup> showed a study that was similar with present study. Bhoj M et al<sup>19</sup> showed sensitivity, specificity, PPV, NPV and accuracy 100% respectively.

For endometrial polyp hysteroscopy showed sensitivity of 100%, a specificity of 100%, PPV 100%, NPV 100% and accuracy 100% in present study. Loiacono et al<sup>3</sup> for endometrial polyp, hysteroscopy showed sensitivity, specificity, PPV, NPV were 100% respectively, that similar with present study. Bhoj M et al<sup>19</sup> also found same parameters 100% for endometrial polyp.

For endometrial hyperplasia the sensitivity, specificity, PPV, NPV and accuracy was 100%, 96.2%, 80%, 100% and 96.7% respectively in present study. Loicano et al<sup>3</sup> showed sensitivity, specificity, PPV, NPV for endometrial hyperplasia were 81%, 96%, 87%, and 93% respectively not compatible with present study. Bhoj M et al<sup>19</sup> showed sensitivity 85.7%, specificity 100%, PPV 100%, NPV 100% and accuracy 97.5% for endometrial hyperplasia.

For endometrial carcinoma hysteroscopy showed a sensitivity, specificity, PPV, NPV and accuracy of 100%, 96.3%, 75.0%, 100% and 96.7% respectively in present study. Loiacono et al<sup>3</sup> showed same parameters for endometrial carcinoma were 63%, 97%, 77%, and 95% respectively that is lower than present study. Bhoj M et al<sup>19</sup> showed same parameters 100% respectively.

As 10% of cases of postmenopausal bleeding had endometrial carcinoma in present study, high sensitivity of hysteroscopy justifies its use in all postmenopausal bleeding cases. Loiacono et al<sup>3</sup> showed 9.8% of cases of postmenopausal bleeding had endometrial carcinoma, this study was almost similar with present study. Bhoj M et al<sup>19</sup> found endometrial carcinoma 10 of patients this study is also similar with present study.

## Conclusion

The study revealed that hysteroscopy and directed biopsy or fractional curettage in some cases is a highly accurate, sensitive, specific, positive predictive value and negative predictive value for diagnosis of cause of postmenopausal bleeding.

Finally concludes that hysteroscopic findings almost correlates with histopathological diagnosis of cause of postmenopausal bleeding in present study.

**Conflict of Interest:** There was no conflict of interest.

**Funding:** There was no funding source for this study.

**Ethical approval:** Institutional Review Board (IRB), Bangabandhu Sheikh Mujib Medical University (BSMMU), Shahbag, Dhaka, Bangladesh.

**Submitted:** 20 December, 2021

**Final revision received:** 18 January, 2023

**Accepted:** 25 January, 2023

**Published:** 01 April, 2023

## References

- Solanki N, Suryarao P, Bhatnagar A. Role of diagnostic hysteroscopy in evaluation of postmenopausal bleeding. *International Journal of Reproduction, Contraception, Obstetrics and Gynecology* [Internet]. Medip Academy; 2019; 23;8:4182.
- Tandulwadkar S, Deshmukh P, Lodha P, Agarwal B. Hysteroscopy in postmenopausal bleeding. *Journal of gynecological endoscopy and surgery*. 2009;1:89-93.
- Loiacono RM, Trojano G, Del Gaudio N, Kardhashi A, Deliso MA, Falco G, Sforza R, Laera AF, Galise I, Trojano V. Hysteroscopy as a valid tool for endometrial pathology in patients with postmenopausal bleeding or asymptomatic patients with a thickened endometrium: hysteroscopic and histological results. *Gynecologic and Obstetric Investigation*. 2015;79:210-16.
- Berek JS, Hacker NF, editors. *Berek and Hacker's gynecologic oncology*. Lippincott Williams & Wilkins, 6<sup>th</sup> Edn; 2010:2010.
- Duncan T, French K, Ansari S, A Clinical Guideline for Assessment of Postmenopausal Bleeding. *Norfolk and Norwich University Hospitals*. Feb 2018; G39: 1-6.
- Lasmar RB, Dias R, Barrozo PR, Oliveira MA, Coutinho ED, da Rosa DB. Prevalence of hysteroscopic findings and histologic diagnoses in patients with abnormal uterine bleeding. *Fertility and sterility*. 2008 Jun 1;89:1803-07.
- Trojano G, Damiani GR, Casavola VC, Loiacono R, Malvasi A, Pellegrino A, Siciliano V, Cicinelli E, Salerno MG, Battini L. The role of hysteroscopy in evaluating postmenopausal asymptomatic women with thickened endometrium. *Gynecology and Minimally Invasive Therapy*. 2018 Jan;7:6.
- Malhotra N, Malhotra J, Saxena R, Bora MN. *Jeffcoate's principles of gynaecology*. Jaypee Brothers, Medical Publishers Pvt. Limited; 2018: 16:595-606.
- Lee DO, Jung MH, Kim HY. Prospective comparison of biopsy results from curettage and hysteroscopy in postmenopausal uterine bleeding. *Journal of Obstetrics and Gynaecology Research*. 2011;37:1423-26.
- O'Connell LP, Fries MH, Zeringue E, Brehm W. Triage of abnormal postmenopausal bleeding: a comparison of endometrial biopsy and transvaginal sonohysterography versus fractional curettage with hysteroscopy. *American journal of obstetrics and gynecology*. 1998 May 1;178:956-61.
- Vardhan S, Mohan S, Ranjan P. Hysteroscopy in Postmenopausal bleeding. *Medical Journal Armed Forces India* [Internet]. Elsevier BV; 2001;57:114–16.
- Sinha P, Rekha PR, Konapur PG, Thamilsevi R, Subramaniam PM. Pearls and pitfalls of endometrial curettage with that of hysterectomy in DUB. *J Clin Diagn Res*. 2011;5:1199-202.
- Jyotshna S, Sanjeeb T. Hysteroscopy in abnormal uterine bleeding vs ultrasonography and histopathology report in perimenopausal and postmenopausal women. *JNMA, Journal of the Nepal Medical Association*. 2016;55:26-28.
- El-Mowafi D, Farid A, El-Badawi A. Transvaginal Sonography and Hysteroscopy Versus Histopathology in Postmenopausal Bleeding. *Obstetrics and Gynecology, Radiology and Pathology Departments, Benha Faculty of Medicine, Egypt*. 2005:1-6.
- Elfayomy AK, Habib FA, Alkabalawy MA. Role of hysteroscopy in the detection of endometrial pathologies in women presenting with postmenopausal bleeding and thickened endometrium. *Archives of gynecology and obstetrics*. 2012;1;285:839-43.
- Pop-Trajkoviæ-Diniæ S, Ljubiæ A, Kopitoviæ V, Antiæ V, Stamenoviæ S, Trninæ-Pjeviæ A. The role of hysteroscopy in diagnosis and treatment of postmenopausal bleeding. *Vojnosanitetski pregled*. 2013;70:747-50.
- Sarvi F, Alleyassin A, Aghahosseini M, Ghasemi M, Gity S. Hysteroscopy: A necessary method for detecting uterine pathologies in post-menopausal women with abnormal uterine bleeding or increased endometrial thickness. *Turk J Obstet Gynecol*. 2016;13:183-88.
- Junnare KK, Desai GJ, Shekhawat GS. Hysteroscopy: an effective tool in post-menopausal bleeding. *International Journal of Reproduction, Contraception, Obstetrics and Gynecology*;8:159-64.
- Bhoj, M. & Yadav, S.K., 2019. Hysteroscopy versus transvaginal ultrasonography: finding the better modality for evaluation of postmenopausal bleeding. *International Journal of Reproduction, Contraception, Obstetrics and Gynecology*, 8, p.1568-74.
- Obuchowski NA, Zhou XH. Prospective studies of diagnostic test accuracy when disease prevalence is low. *Biostatistics*. 2002 Dec 1;3:477-92.
- Wani RT. Socioeconomic status scales-modified Kuppuswamy and Udai Pareekh's scale updated for 2019. *J Family Med Prim Care* 2019;8:1846-69.
- Alfhaily F, Ewies AA. The first-line investigation of postmenopausal bleeding: transvaginal ultrasound scanning and endometrial biopsy may be enough. *International journal of gynecological cancer: official journal of the International Gynecological Cancer Society*. 2009;19:892-95.
- Guida M, Bramante S, Acunzo G, Lavitola G, Sparice S, Cerrota G, Nappi C. Evaluation of endometrial carcinoma using hysteroscopy and transvaginal echography. *Tumori*. 2003; 1;89:253-54.
- Babacan A, Gun I, Kizilaslan C, Ozden O, Muhcu M, Mungen E, Atay V. Comparison of transvaginal ultrasonography and hysteroscopy in the diagnosis of uterine pathologies. *International journal of clinical and experimental medicine*. 2014;7:764-69.